

Solitary retinocytoma in a seven year old boy

Wanyonyi M, Njambi L, Kimani K, Gachago M, Njuguna M

Department of Ophthalmology, Faculty of Medicine, University of Nairobi, P.O. Box 19676-00202, Nairobi, Kenya

Corresponding author: Dr. L. Njambi. email : drnjambi@yahoo.com

ABSTRACT

Retinal astrocytoma is a rare benign tumour of astrocytes in the neurosensory retina. Detection usually occurs in childhood or adolescence. In this age group the diagnosis of solitary cases can be challenging as they may mimic retinoblastoma. However, there are cases that have been diagnosed in adulthood. In this case report, a seven year old boy presented with long standing history of leukocoria. The discussion highlights the management and distinguishing features with other causes of leukocoria.

INTRODUCTION

Astrocytic hamartomas are typically white, well-circumscribed, elevated lesions arising in single or multiple areas of the retina and epi- or peripapillary optic nerve. It is extremely slow-growing and is usually asymptomatic unless the macula is involved¹. Some cases may present with squint or poor vision. They may occur as solitary (isolated) retinal astrocytoma or it may be syndromic, in association with tuberous sclerosis². The unilateral cases are usually unifocal, sporadic and non-syndromic. However, the bilateral cases (50%) are usually multifocal and associated with tuberous sclerosis or neurofibromatosis^{3,4}.

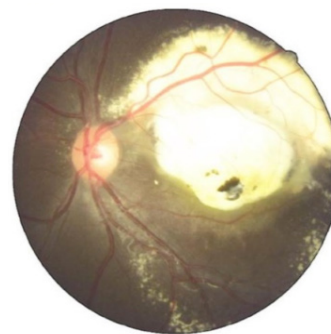
Solitary lesions appear as white superficial lesion associated with retinal oedema, exudates and calcification. The ocular ultrasound of astrocytoma resembles that of retinoblastoma. Clinical resemblance with retinoblastoma has resulted in cases whereby enucleation has been done for suspected retinoblastoma¹. We report a case of solitary retinal astrocytoma in a seven year old boy.

CASE REPORT

A 7 year old boy was referred to Kenyatta National Hospital, Kenya from another health facility with a five year history of white reflex in the left eye. There was no redness, squint, proptosis, decreased visual acuity or systemic complaints. The child had normal birth and development. There past medical and ocular history was not significant. On examination, the boy was in good general condition. He had a normal systemic examination with no skin lesions. Visual acuity was 6/6 in the right eye and counting fingers one metre in the left eye. Extra ocular muscle movement was free in both eyes. There was no squint or proptosis. Intraocular pressure was 15mmHg in the right eye and 16mmHg in the left eye. Anterior segment examination was normal in both eyes. The right eye had a normal posterior segment while the left eye, had a whitish mass in the posterior pole, which was located just below the superior temporal arcade. It was one disc diameter from the optic disc and

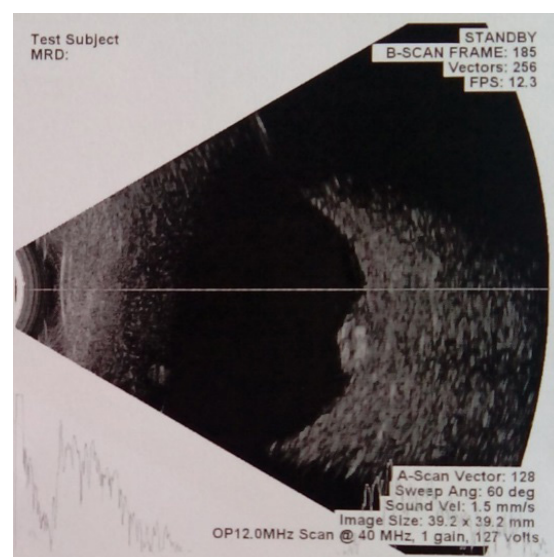
was overlying the macula region. The mass was 3 disc diameters wide and 2 ½ disc diameters high. There were exudates below and above the mass extending to above the superior temporal arcade as shown in the fundus (Figure 1).

Figure 1: Shows the fundus photograph of the left eye



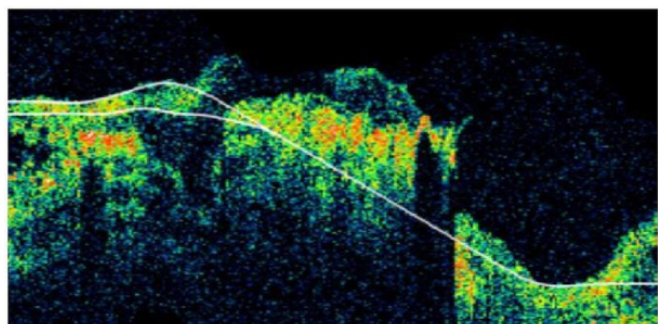
B scan ultrasound of the left eye (Figure 2) showed a raised hyperechoic retinal opacity with shadowing and was persisting on reduced gain. The retina overlying the mass was detached. The A scan showed high reflectivity spikes.

Figure 2: B scan ultrasound of the left eye



Optical Coherent Tomography (OCT) of the left eye (Figure 3) had poor image quality due to poor fixation.

Figure 3: OCT of the left eye



Differential diagnosis of this calcified retinal mass considered in this patient included retinal astrocytoma, retinoblastoma and choroid osteoma (osseous choristoma). A diagnosis of solitary retinal astrocytoma was made based on the long duration, asymptomatic nature, the presence of a mass with calcification and exudates and the ocular ultrasound features resembling retinoblastoma. Management for the patient included serial fundus photography and ocular ultrasound to monitor the mass and protective eyewear. Follow up reviews shows that mass has not progressed.

DISCUSSION

Few cases of solitary astrocytoma are reported in literature. A clinical diagnosis without histology like in this patient is usually presumptive. We highlight features that lead to this diagnosis, ruling out other causes of leukocoria. The age of presentation for solitary astrocytoma varies from one month to 45 years although most cases are diagnosed in children and adolescents.

In a review of 42 intraocular astrocytomas confirmed by histology, 57% were associated with tuberous sclerosis, 14% were related to neurofibromatosis and 29% were sporadic cases⁵. In this case report, the patient had no systemic or other ocular findings, making the diagnosis of solitary tumour more probable.

Clinical differentiation from retinoblastoma and amelanotic melanoma can be difficult. Retinal traction, retinal epithelial cells alteration and extensive yellow retinal exudation are typically found with astrocytoma but not retinoblastoma³. The long duration of the history in this patient, presence of calcification on B scan ocular ultrasound and the fundus photography findings of a solitary juxtapapillary mass with massive exudation supported a clinical diagnosis of solitary astrocytoma.

Despite the presence of a calcified mass in a child, the diagnosis of retinoblastoma was low in the list of differential diagnoses because of several reasons. The duration of presentation in retinoblastoma is much shorter, average of 24 months in unilateral cases. Those

who present later usually have proptosis with or without metastasis. Diffuse infiltrating type may take longer to be noticed and thus present at such an age as our patient, but usually this would present as diffuse infiltration of the retina rather than a discrete mass⁶. Retinal exudates are also not typical of retinoblastoma⁷.

In this case, the age and race of the patient did not support the probability of amelanotic melanoma, which are mostly found in older Caucasians. On ultrasonography, typically they show an acoustically silent zone within the melanoma, choroidal excavation, shadowing in the orbit and do not have features of calcification⁸. Solitary astrocytomas are typically located in the sensory retina unlike melanomas which are found in the choroid. Half of the cases are calcified and may shed cells into the vitreous making clinical diagnosis more suspect³.

A choroidal osteoma though highly calcified due to the presence of bone is typically found in young females in the second or third decade of life located juxtapapillary. It is usually relatively flat appearing as a calcified plaque at the level of the choroid unlike our patient who had an elevated mass arising from the retina⁹.

Another differential diagnosis is ocular toxocariasis, which may present as posterior pole granuloma. Vitreous inflammation may present as low amplitude echoes on B-scan. Other B-scan findings in ocular toxocariasis may include vitreous bands, retinal folds and tractional retinal detachment¹⁰. The most consistent ultrasound finding in toxocara is a highly refractive retinal mass in the periphery or posterior pole which may be calcified and has a main characteristic the adherence of vitreous membranes¹¹.

There are two types of acquired solitary astrocytoma, progressive and stationary type. The progressive form causes intraocular damage with exudative retinal detachment, neovascular glaucoma, central retinal vein occlusion and extensive tumour necrosis with secondary intraocular inflammation that ultimately results in a painful blind eye³. Our patient appeared to have the stable non progressive form supported by the long history without features of progression and has remained stable on follow up.

No treatment is required for retinal astrocytoma. There may be limited enlargement of the mass and they do not metastasize. One retrospective review of seven patients with presumed solitary retinal astrocytic proliferation (with a median follow-up of 6 years) showed that the tumour remained stable in six patients and gradually disappeared in one patient^{2,4}.

Most histologically confirmed diagnosis are removed surgically because of blindness and pain or because they mimic retinoblastoma, amelanotic melanoma or metastatic tumours^{3,7}.

REFERENCES

1. Sharma A, Ram J, Gupta A. Solitary retinal astrocytoma. *Acta Ophthalmologica*. 1991; **69** (1): 113–116.
2. Ali MJ, Honavar SG, Naik MN. Retinal astrocytic hamartoma and Bourneville's disease. *Oman J Ophthalmol*. 2012; **5**(3): 198-199.
3. Takafumi F, Tomayoshi H, Kiyoshi S Asuka T, Kuniko A, *et al*. Solitary retinal astrocytoma: A case series. *Ojpathology*. 2013; **3**: 60-64.
4. Shields J, Bianciotto C, Kivela T, Shields C. Presumed solitary circumscribed retinal astrocytic proliferation. *Arch Ophthalmol*. 2011; **129** (9): 1189-1194.
5. Pussateri A, Margo CE. Intraocular astrocytoma and its differential diagnosis. *Arch Pathol Lab Med*. 2014; **128**: 1250-1254.
6. Abramson DH, Beaverson K, Sangani P, Vora RA, Lee TC, Hochberg HM, *et al*. Screening for retinoblastoma: presenting signs as prognosticators of patients and ocular survival. *Pediatrics*. 2003; **112** (6): 1248 -1255.
7. Shields CL, Shields JA, Eagle Jr RC, Cangemi F. Progressive enlargement of acquired retinal astrocytoma in 2 cases. *Ophthalmology*. 2004; **111** (2): 363- 368.
8. Singh P, Singh A. Choroidal melanoma. *Oman J Ophthalmol*. 2012; **5**(1): 3-9.
9. Kadrmas EF, Weiter JJ. Choroidal osteoma. *Int Ophthalmol Clin*. 1997; **37**(4):171-182.
10. Rodman J, Pizzimenti J. *In vivo* diagnostic imaging of ocular toxocariasis *Clin Exper Optometry*. 2009; **92**(2): 146–149.
11. Morais FB, Maciel AL, Arantes TE, Muccioli C, Allemann N. Ultrasonographic findings in ocular toxocariasis. *Arq Bras Oftalmol*. 2012; **75**(1):43-47.